







Updated practical recommendations for the peripherally inserted central catheter in newborns

Atualização das recomendações da prática quanto ao cateter central de inserção periférica em recém-nascidos

Actualización de las recomendaciones de la práctica sobre el catéter central de inserción periférica en neonatos

Ludmylla de Oliveira Beleza^I ; Laiane Medeiros Ribeiro^I ; Christiane Inocência Vasques^I ;
Amanda Margatho^{II} ; Guilherme Brasil^{III} ; Kassandra Costa^{IV} 

^IUniversidade de Brasília, Brasília, DF, Brazil; ^{II}Universidade de São Paulo, Ribeirão Preto, SP, Brazil;

^{III}Centro Universitário do Distrito Federal, Brasília, DF, Brazil; ^{IV}Hospital Universitário de Brasília, Brasília, DF, Brazil

ABSTRACT

Objective: to discuss the most current recommendations for nursing practice in the management of the peripherally inserted central catheter (PICC) in newborns (NBs). **Content:** care for NBs with PICCs has undergone several changes as regards measuring the size of the catheter to be inserted and visualizing the vein to be punctured, factors influencing choice of insertion site, monitoring for catheter migration, confirming PICC tip position, and other precautions for device maintenance and removal. **Conclusion:** knowledge of PICC management in newborns has advanced greatly, but still features gaps to be explored. Care for NBs who receive a PICC is expected to improve.

Descriptors: Nursing; Catheterization, Peripheral; Infant, Newborn; Diffusion of Innovation.

RESUMO

Objetivo: discutir sobre as recomendações para prática de enfermagem mais atuais no manejo de cateter central de inserção periférica (PICC) em recém-nascidos (RNs). **Conteúdo:** a assistência ao RN com PICC vem sofrendo diversas alterações em relação às formas de mensuração do tamanho do cateter a ser inserido e de visualização da veia a ser puncionada, aos fatores que influenciam a escolha do sítio de inserção, ao acompanhamento da migração do cateter, à confirmação da ponta do PICC e a outros cuidados de manutenção e remoção do dispositivo. **Conclusão:** houve uma grande evolução do conhecimento referente ao manejo do PICC na população neonatal, mas ainda existem lacunas de conhecimento a serem exploradas. Espera-se uma melhoria da assistência ao RN que receberá um PICC.

Descritores: Enfermagem; Cateterismo Periférico; Recém-Nascido; Difusão de Inovações.

RESUMEN

Objetivo: discutir las recomendaciones más actuales para la práctica de enfermería sobre el manejo de catéteres centrales de inserción periférica (PICC) en recién nacidos (RN). **Contenido:** la asistencia al RN con PICC ha sufrido varios cambios en relación con las formas de medir el tamaño del catéter a insertar y la visualización de la vena a puncionar, los factores que influyen en la elección del sitio de inserción, el seguimiento de la migración del catéter, la confirmación de la punta del PICC y otras precauciones de mantenimiento y extracción del dispositivo. **Conclusión:** ha habido una gran evolución del conocimiento sobre el manejo de PICC en la población neonatal, sin embargo, aún existen brechas de conocimiento por explorar. Se espera una mejora en la asistencia al RN que recibirá un PICC.

Descriptor: Enfermería; Cateterismo Periférico; Recién Nacido; Difusión de Innovaciones.

INTRODUCTION

The peripherally inserted central venous catheter (PICC) has been used in Brazil since 1990, but its use has become more frequent in the neonatal area from 2000 onwards¹. PICC insertion in neonatology enables safe, effective, prolonged, and comfortable intravascular venous access to a fragile population vulnerable to iatrogenic risks^{2,3}.

The use of PICC in newborns (NBs) has an impact on reducing the risk of phlebitis, the number of repeated punctures with peripheral intravenous catheters, and, consequently, reducing pain and suffering^{3,4}.

However, the insertion and maintenance of PICC are complex procedures and its use is related to a large repertoire of complications that can increase neonatal morbidity and mortality⁵. For this reason, the nurse must know the specifics of PICC, qualify for the insertion and handling of this catheter, establish protocols in hospital institutions, and always keep up-to-date on the technological innovations used in the management of this PICC to provide effective and quality care^{1,2}.

Corresponding author: Ludmylla de Oliveira Beleza. E-mail: ludmyllab@hotmail.com
Scientific Editor: Cristiane Helena Gallasch; Associate Editor: Juliana Amaral Prata

Many of these technological and care innovations related to PICC have been standing out on the international scenario and have been ratified by the recent publication of guidelines and research. However, the latest Brazilian publications do not present changes in measurement techniques, insertion, and maintenance of PICC in newborns^{2,6,7}.

In this context, this article aims to discuss the innovations in the practice recommendations in the management of PICC in neonates.

CONTENT

PICC indications in neonatology

The indication for insertion of central vascular access devices such as PICC in NBs was changed to when a need for intravascular therapy of at least five days is anticipated, as there is a need for high-quality clinical trials to indicate midline catheters in this population⁸.

Measurement of the PICC length to be inserted

Traditionally, the extension/length of the catheter that will be inserted into the vessel is measured according to external anatomical landmarks, always starting from the probable insertion site^{8,9}. However, the use of this measurement technique has led to the need for adjustments (traction) of the catheter due to poor positioning of the tip in approximately 65.9 to 73.5% of insertions¹⁰⁻¹². This need for adjustments can reach 97.3% in NBs who weigh less than 617 grams¹².

Thus, formulas were developed to estimate the length of the PICC to be introduced in an attempt to reduce tractions after insertion, correlating it with the weight and height of NBs. A study¹¹ evaluated 214 NBs and estimated different formulas depending on the PICC insertion site. The authors reported the following formula for insertion into foot veins “measurement to be inserted (cm) = 16 + 4.27 x body weight (kg)”; for insertion into the femoral vein, the “measurement to be inserted (cm) = 9.8 + 1.7 x body weight (kg)”; in the popliteal vein, the “measurement to be inserted (cm) = -0.3 + 0.45 x height (cm)”; in the hand veins, the “measurement to be inserted (cm) = 4.46 + 0.32 x height (cm)”; and in the axillary vein, the “measurement to be inserted (cm) = 1 + 0.18 x height (cm)”. The accuracy of the proposed formulas was evaluated in 102 NBs and there was a reduction in the need for catheter traction after insertion, especially when the insertion site was performed in lower limb (LL) veins¹¹.

Another recent study reviewed the medical records of 790 patients and established a formula that assigns a constant value according to the vein to be punctured, which considers the vein to be punctured, the weight range in which the NB was born (from 1000 to 1500 g, for example), and the birth weight. The PICC length to be inserted would be equal to Section (vein constant) + (weight constant x weight/100). This formula demonstrated an accuracy greater than 90% among NBs evaluated¹³.

These studies present a safe and assertive alternative to the measurement that uses anatomical landmarks, innovating by enabling the reduction of painful and stressful procedures by reducing the need for PICC traction after insertion and manipulation of NBs^{11,13}.

Visualization of the vein to be punctured

There is a recommendation that an ultrasound (US) device be used to assess the vein that will be punctured in terms of its caliber (not exceeding 30-45% of the vessel) and whether there are abnormalities in its extension, such as occlusions and thrombosis^{8,14-16}.

A retrospective study from the United States aimed to describe the use of US in the PICC insertion. It presented the technique of visualization, puncture, and PICC insertion in real-time, demonstrating the simplicity and accuracy of the technique¹⁴, as shown in Figure 1. In that study, the success rate was 100% in a sample consisting of 10 NBs, with multiple previous unsuccessful vascular access attempts¹⁴.

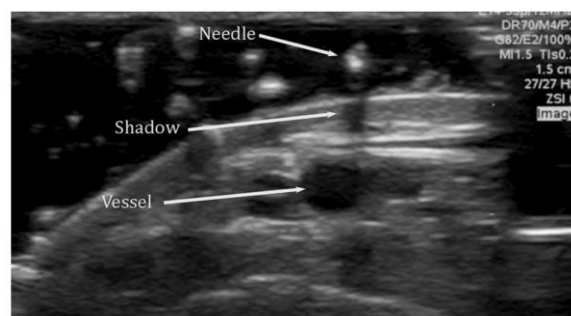


FIGURE 1: Transverse view when placing the US transducer lightly on the skin that will receive the puncture for the catheter insertion¹⁴.

Few studies have been found in which devices were used to facilitate the visualization of veins when inserting PICC in NBs, as well as the use of US for this purpose^{14,15}. Despite this, a clinical trial demonstrated the effectiveness of near-infrared and transluminator equipment in the insertion of peripheral catheters in NBs¹⁷, and there is a recommendation to use devices for this purpose^{8,16}.

Factors influencing the choice of the insertion site

Recent research with NBs¹⁸ did not identify any difference in the prevalence of complications related to the use of PICC relative to the insertion site. However, the results of a meta-analysis¹⁹ demonstrated that the rates of complications related to the use of PICC in NBs are higher in catheters inserted in upper limb (UL) veins when compared to those inserted in LL, mainly risk of non-elective removal and poor positioning¹⁹.

Studies have shown that the risk of thrombosis increases in NBs who underwent abdominal surgery^{8,19} and that severe thrombotic complications can occur in surgical patients with PICC inserted in LL²⁰. This last fact can be explained by the need for longer maintenance of PICC in surgical patients due to probable abdominal hypertension after local surgery and the resulting decrease in femoral blood flow, which would increase the risk of thrombosis due to venous stasis¹⁹.

Therefore, although the veins of upper limbs are the preferred insertion sites for PICC insertion, it is important to consider performing this procedure initially in the LL of non-surgical NBs¹⁶. In NBs undergoing abdominal surgery, it is recommended to avoid PICC insertions in LL to reduce the occurrence of some complications related to the catheter⁸.

Monitoring of catheter migration

PICC constantly migrates within the vessel, regardless of the insertion site. Studies have found that elbow flexion and adduction and abduction movement at 180° of the upper limb with a catheter during x-ray results in movement of the tip towards the heart^{9,21,22}. Research with 60 neonates shows that limb movement leads to migration of the catheter tip according to the punctured vein, and if the catheter is inserted below the elbow and is flexed, its tip migrates towards the heart when compared to the one performed in elbow extension; and if the limb is adducted towards the body, there is migration into or out of the heart if the veins accessed are basilic and cephalic, respectively²¹.

Thus, most of the currently available evidence emphasizes with greater support that a flexed elbow position should be adopted to perform the x-ray confirmation of the tip of the PICC inserted in UL, as this is the most physiological, common, and natural position for the NB, in addition to being the longest in most insertion sites^{9,12}.

It seems safe and even recommendable to perform x-rays in patients who received PICC in UL in a flexed elbow and adducted shoulder position. This constant tip migration also confirms the need for routine and frequent radiological monitoring of the PICC positioning.

Ultrasound, when available at the unit, can be used to insert the PICC and during its migration to the desired site, as its use is associated with an improvement in insertion success rates and a decrease in the number of punctures and complication rates^{8,10}.

PICC tip position

There is very robust evidence linking the increase in complication rates with non-central positioning of the PICC tip, especially obstructions, extravasation, other mechanical complications, phlebitis, and non-elective removal^{5,8,23,24}. Complications that culminate in non-elective PICC removal can lead to early interruption of intravenous therapy, increased costs, increased hospital stay and stress, and negative impacts on the NBs' health^{12,25}.

For this reason, it is essential to ensure that the PICC tip is positioned as centrally as possible, ideally in the superior or inferior vena cava and close to the cavoatrial junction, and its visualization is traditionally performed by x-ray after its insertion^{8-10,12,19}. However, confirmation of the tip by x-ray has been considered inadequate due to the time it can take to perform this procedure and the amount of radiation to which NBs are exposed^{12,26,27}.

As safer, more reliable, and cheaper alternatives, the confirmation of the PICC tip location could be performed in real-time through US and/or intracavitary electrocardiogram (IC-ECG)⁸. The rate of need for PICC adjustment/traction after its insertion is significantly lower when its tip is verified by US compared to x-ray. In addition, the PICC tip location is performed in a shorter time interval when using US^{12,22} and its accuracy can reach up to 94%^{9,24}. US also has the advantages of not exposing NBs to radiation, real-time assessment, lower incidence of misplacement of the tip, less manipulation of NBs, and immediate identification of migration and repositioning

of catheters to an appropriate position.^{10,15,22} However, there are obstacles to the implementation of this technology, such as the availability of equipment in the units and the need for training and accreditation of the US operator^{8,9,14,28}.

The IC-ECG works by placing electrodes at three points on the thorax, and one of the sensors connected to them is removed during insertion and placed in contact with the distal end of the PICC^{26,27,29,30}, as shown in Figure 2. As the catheter tip moves towards the heart, the P wave of the electrocardiogram changes and undergoes an increase in amplitude until it exceeds that of the QRS complex when it reaches the cavoatrial junction (Figure 3); the P wave decreases when the PICC tip enters the heart and can become bidirectional or negative^{26,29,30}.

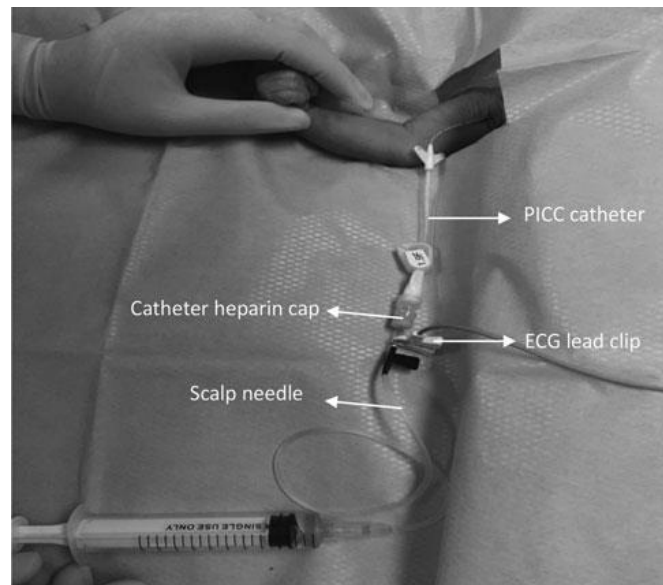


FIGURE 2: Demonstration of how the materials capable of instrumenting the IC-ECG30 are organized³⁰.

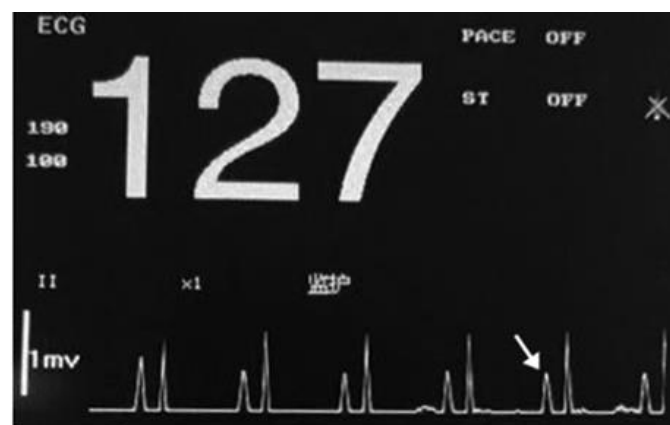

FIGURE 3: P-wave amplitude exceeding the QRS complex, a phenomenon that can be verified when the catheter tip reaches the cavoatrial junction²⁹.

Studies that compared the accuracy of IC-ECG with x-ray have shown a number ranging from 74-95%^{26,29,30}, with a sensitivity of 94.26-97% and specificity of 85.5-100%^{26,29}. Other advantages of this method: it is non-invasive, there is no exposure to radiation, and the necessary equipment is easy to handle by trained nurses^{26,27,29}. The complication rate in a study that compared this method with the anatomical landmark was lower in the IC-ECG group²⁹. Importantly, some

factors can lead to failures, such as the non-appearance of the P wave, active patient movement, and interference from other nearby electromagnetic equipment^{26,29,30}.

Non-invasive maneuvers to aid progression and reposition the PICC tip

Regarding the PICC progression, a recent Brazilian article shows the application of a shoulder movement maneuver capable of assisting it in the right hemi-clavicular region of NBs, which consists of three steps to increase the subclavian space between the first rib and the clavicle, reducing possible local compression: elevation (pressing the axillary region), protraction (pressing the scapular region postero-anteriorly, bringing the shoulder forward), and lowering (pressing it lightly in the cephalocaudal direction). There was statistical significance with the better progression of the catheter inserted into the right cephalic vein when the maneuver was performed ($p < 0.05$)⁶.

In NBs, there is a recommendation to use non-invasive means for its correction whenever the PICC tip is poorly positioned inside the vessel, such as elevating the head of the bed if the tip is in the jugular vein, lying on the opposite side with the head elevated if it is in brachiocephalic vein, or delicate flushing and fluid infusion⁸. Mispositioning adjustments of the tip of 10 PICCs only with the movement of the limb in which it was introduced have been described. Thus, PICCs inserted in the basilic vein that went to neck veins showed a successful tip migration in 9 out of 10 catheters with the following maneuvers: the limb was abducted at the shoulder and the elbow extended as far as possible, which led to the tip in a more peripheral direction; then, the shoulder was adducted, and the elbow flexed so that the tip went to the central position. A catheter inserted in the cephalic vein, which bent in the subclavian vein, returned to the central position when adducting the limb at shoulder level and extending the elbow as far as possible and, soon after, abducting the shoulder and flexing the elbow²¹.

Other precautions related to PICC insertion, maintenance, and removal

In general, catheters should not be cut unless recommended by the manufacturer³¹. Even with the recommendation, the practice of cutting the catheter leads to changes in its tip, which may or may not have negative clinical consequences³². A study carried out with 634 adults found an association between cutting the PICC before its insertion and deep vein thrombosis (DVT), that is, when the PICC is cut, there is 5 times more chance of developing DVT compared to uncut catheters³³. A systematic review with a hospitalized neonatal population showed that it is not possible to affirm that the procedure of cutting catheters is safe and that guidelines based on relevant evidence were not found to guarantee safety in this procedure³⁴.

Regarding the insertion procedure, a Brazilian quasi-experimental study demonstrated that the use of a thermal blanket during the PICC insertion in NBs can prevent and even correct the hypothermia resulting from this procedure³⁵.

The need for flushing (administration of a quick solution to wash catheter) to ensure the PICC permeability was also evaluated in a systematic review, and no type of recommendation for the neonatal population could be provided due to the lack of evidence for carrying out very varied practices³⁶. However, flushing with saline solution (without preservatives, which are toxic for NBs), preferably pulsatile, is recommended in all vascular devices before and after administration of medications⁸. In addition, the use of continuous solutions with 0.5U/kg heparin in all central catheters for NBs is recommended⁸.

No descriptions of the use of PICC with anti-thrombogenic materials in NBs have been found. However, an overview states that there is still a need for more trials to establish the effectiveness, efficiency, and safety of the products used in these catheters³⁷.

Regarding the prevention of infection, no reports have been found on the safety and effectiveness of PICCs impregnated with antimicrobials/chlorhexidine in the neonatal population, but locks with vancomycin and heparin led to excellent results in a recent study carried out with NBs³⁸.

The prudent use of chlorhexidine is also recommended during skin asepsis in preterm and low birth weight NBs in the first 14 days of life due to the occurrence of chemical burns, as well as infants younger than 2 months, as there are records of systemic absorption. The antiseptic should be removed soon after use and time of action, and iodine-based products should not be used for asepsis in premature infants^{8,39}.

Transparent dressings for PICCs inserted in NBs are still recommended not to be changed routinely, but only when dirty or loose, and the use of dressings and integrated devices that eliminate the need for sutures for proper fixation of the catheter are encouraged^{8,40}. An Italian neonatal unit obtained a reduction from 35 to 20% of accidental displacement when using cyanoacrylate glue with the transparent dressing to fix the PICC, being the use of the glue safe, cheap, and easy to remove¹⁶. However, further studies must be carried out to confirm the effectiveness of this material.

The neonatal population has a high risk of skin injury and hence the use of barrier/protective solutions on the skin is advised before applying the dressing^{8,40}. Dressings impregnated with chlorhexidine should be avoided, as they are associated with contact dermatitis in NBs, especially in premature ones⁸.

Another current recommendation is that the PICC and other central catheters be removed with the NB in the supine position (or even Trendelenburg if not premature), performing compression with sterile gauze and maintaining an occlusive dressing, such as gauze with petrolatum, for 24 hours to prevent air embolism⁸.

CONCLUSION

In recent years, there has been a great evolution of knowledge regarding the management of PICC in the neonatal population. There is a better understanding of the catheter behavior inside the vessel, new ways of measuring the catheter length to be inserted, use of technology in insertion procedures and confirmation of the catheter tip, catheters and dressings of different materials used in other populations cannot be used in NBs. Care that was previously considered essential, such as flushing at the same time and cutting the catheter before insertion, have been evaluated in terms of their real needs and risks. All these innovations have reduced complication rates, which certainly reduces the morbimortality and suffering of NBs.

Unfortunately, even though some studies may date back more than 5 years, the information and their recommendations do not seem to be reaching the direct care of neonatal patients in many institutions in Brazil. Thus, it is expected that this article transforms the knowledge acquired through its updates into a direct improvement in the quality of nursing care for newborns who receive the PICC.

REFERENCES

1. Freitas EM, Nunes ZB. The nurse and the practice of peripherally inserted central catheter in neonatal care. *Reme* [Internet]. 2009 [cited 2021 May 20]; 13(2):1-10. Available from: <https://cdn.publisher.gn1.link/reme.org.br/pdf/v13n2a08.pdf>.
2. Prado NCC, Silva RAR, Costa RHS, Delgado MF. Non-elective removal of the peripherally inserted central catheter in the neonatal unit. *Rev Eletr Enferm* [Internet]. 2018 [cited 2021 May 20]; 20:v20a13. DOI: <https://doi.org/10.5216/ree.v20.45559>.
3. Di Santo MK, Takemoto D, Nascimento RG, Nascimento AM, Siqueira E, Duarte CT, et al. Peripherally inserted central venous catheter: alternative or first choice vascular access? *J Vasc Bras* [Internet]. 2017 [cited 2021 May 20]; 16(2):104-12. DOI: <http://dx.doi.org/10.1590/1677-5449.011516>.
4. Ainsworth S, McGuire W. Percutaneous central venous catheters versus peripheral cannula for delivery of parenteral nutrition in neonates. *Cochrane Database Syst Rev* [Internet]. 2015 [cited 2021 May 20]; 10:CD004219. Available from: <https://www.cochranelibrary.com/cdsr/doi/10.1002/14651858.CD004219.pub3/epdf/full>.
5. Patil K, Dhaded SM, Bhandankar M. A 1-Year Study on Association between Peripherally Inserted Central Catheter Tip Position and Complications in Neonates. *J Indian Assoc Pediatr Surg* [Internet]. 2020 [cited 2021 May 20]; 25(5):276-9. DOI: https://doi.org/10.4103/jiaps.JIAPS_87_19.
6. Nobre KSS, Cardoso MV LML, Rodrigues EC, Melo GM. Progression of peripherally inserted central catheter in hemi clavicular region of newborns. *Reme* [Internet]. 2020 [cited 2021 Jun 05]; 21:e42980. DOI: <http://dx.doi.org/10.15253/2175-6783.20202142980>.
7. Rangel RJM, Castro DS, Amorim MHC, Zandonade E, Christoffel MM, Primo CC. Practice of Insertion, Maintenance and Removal of Peripheral Inserted Central Catheter in Neonates. *R. pesq cuid fundam* [Internet]. 2019 [cited 2021 Jul 02]; 11(2):278-84. DOI: <https://doi.org/10.9789/2175-5361.2019.v11i2.278-284>.
8. Gorski LA, Hadaway L, Hagle ME, Broadhurst D, Clare S, Kleidon T, et al. Infusion therapy standards of practice. *J Infus Nurs* [Internet]. 2021 [cited 2021 May 20]; 44(suppl 1):S1-S224. DOI: <https://dx.doi.org/10.1097/NAN.0000000000000396>.
9. Zaghoul N, Watkins L, Choi-Rosen J, Perveen S, Kurepa D. The superiority of point of care ultrasound in localizing central venous line tip position over time. *Eur J Pediatr* [Internet]. 2019 [cited 2021 May 20]; 178(2):173-9. DOI: <https://doi.org/10.1007/s00431-018-3269-9>.
10. Oleti T, Jeeva Sankar M, Thukral A, Sreenivas V, Gupta AK, Agarwal R, et al. Does ultrasound guidance for peripherally inserted central catheter (PICC) insertion reduce the incidence of tip malposition? - a randomized trial. *J Perinatol* [Internet]. 2019 [cited 2021 May 21]; 39(1):95-101. DOI: <https://doi.org/10.1038/s41372-018-0249-x>.
11. Chen IL, Yang MCO, Chen FS, Chung MY, Chen CC, Liu YC, et al. The equations of the inserted length of percutaneous central venous catheters on neonates in NICU. *Pediatrics and Neonatology* [Internet]. 2019 [cited 2021 May 20]; 60(3):305-10. DOI: <https://doi.org/10.1016/j.pedneo.2018.07.011>.
12. Huang HC, Su LT, Liu YC, Chang HY, Ou-Yang MC, Chung MY, et al. The role of ultrasonography for detecting tip location of percutaneous central venous catheters in neonates-a single-center, prospective cohort study. *Pediatr Neonatol* [Internet]. 2021 [cited 2021 Jun 02]; 62(3):265-70. DOI: <https://doi.org/10.1016/j.pedneo.2021.01.006>.
13. Kim DY, Park HR. Estimating the Insertion Depth of a Peripherally Inserted Central Catheter in Newborns Using Weight and Gestational Age Measurements. *J Perinat Neonatal Nurs* [Internet]. 2021 [cited 2021 Jul 18]; 35(4):362-8. DOI: <https://doi.org/10.1097/JPN.0000000000000585>.

14. Johnson KN, Thomas T, Grove J, Jarboe MD. Insertion of peripherally inserted central catheters in neonates less than 1.5 kg using ultrasound guidance. *Pediatr Surg Int* [Internet]. 2016 [cited 2021 May 21]; 32(11):1053-7. DOI: <https://doi.org/10.1007/s00383-016-3959-1>.
15. Abdeyazdan Z, Sheikhan-Sudani E, Sadeghnia A, Talakoub S. Effect of using static ultrasound technique on peripherally inserted central catheters' insertion success rate in neonates in a neonatal intensive care unit. *Iran J Nurs Midwifery Res* [Internet]. 2014 [cited 2021 May 20]; 19(6):643-6. Available from: <https://www.ncbi.nlm.nih.gov/pmc/articles/PMC4280730/>.
16. Barone G, Pittiruti M. Epicutaneo-caval catheters in neonates: New insights and new suggestions from the recent literature. *J Vasc Access* [Internet]. 2020 [cited 2021 Jul 18]; 21(6):805-9. DOI: <https://doi.org/10.1177/1129729819891546>.
17. Çağlar S, Büyükyılmaz F, Bakoğlu İ, İnal S, Salihoglu Ö. Efficacy of Vein Visualization Devices for Peripheral Intravenous Catheter Placement in Preterm Infants: A Randomized Clinical Trial. *J Perinat Neonatal Nurs* [Internet]. 2019 [cited 2021 Jun 05]; 33(1):61-7. DOI: <https://doi.org/10.1097/JPN.0000000000000385>.
18. Elmekawi A, Maulidi H, Mak W, Aziz A, Lee KS. Outcomes of upper extremity versus lower extremity placed peripherally inserted central catheters in a medical-surgical neonatal intensive care unit. *J Neonatal Perinatal Med* [Internet]. 2019 [cited 2021 May 24]; 12(1):57-63. DOI: <https://doi.org/10.3233/NPM-1817>.
19. Chen H, Zhang X, Wang H, Hu X. Complications of upper extremity versus lower extremity placed peripherally inserted central catheters in neonatal intensive care units: A meta-analysis. *Intensive Crit Care Nurs* [Internet]. 2020 [cited 2021 May 24]; 56:102753. DOI: <https://doi.org/10.1016/j.iccn.2019.08.003>.
20. Kisa P, Ting J, Callejas A, Osioviich H, Butterworth SA. Major thrombotic complications with lower limb PICCs in surgical neonates. *J Pediatr Surg* [Internet]. 2015 [cited 2021 May 24]; 50(5):786-9. DOI: <https://doi.org/10.1016/j.jpedsurg.2015.02.043>.
21. Nadroo AM, Glass RB, Lin J, Green RS, Holzman IR. Changes in upper extremity position cause migration of peripherally inserted central catheters in neonates. *Pediatrics* [Internet]. 2002 [cited 2021 May 12]; 110(1 Pt 1):131-6. DOI: <https://doi.org/10.1542/peds.110.1.131>.
22. Katheria AC, Fleming SE, Kim JH. A randomized controlled trial of ultrasound-guided peripherally inserted central catheters compared with standard radiograph in neonates. *J Perinatol* [Internet]. 2013 [cited 2021 May 20]; 33(10):791-4. DOI: <https://doi.org/10.1038/jp.2013.58>.
23. Yu X, Yue S, Wang M, Cao C, Liao Z, Ding Y, Huang J, Li W. Risk Factors Related to Peripherally Inserted Central Venous Catheter Nonselective Removal in Neonates. *Biomed Res Int* [Internet]. 2018 [cited 2021 May 20]; 2018:3769376. DOI: <https://doi.org/10.1155/2018/3769376>.
24. Telang N, Sharma D, Pratap OT, Kandraju H, Murki S. Use of real-time ultrasound for locating tip position in neonates undergoing peripherally inserted central catheter insertion: A pilot study. *Indian J Med Res* [Internet]. 2017 [cited 2021 May 20]; 145(3):373-6. Available from: <https://www.ncbi.nlm.nih.gov/pmc/articles/PMC5555067/>.
25. Costa P, Kimura AF, Brandon DH, Damiani LP. Predictors of Nonelective Removal of Peripherally Inserted Central Catheters in Infants. *Biol Res Nurs* [Internet]. 2016 [cited 2021 May 20]; 18(2):173-80. DOI: <https://doi.org/10.1177/1099800415590856>.
26. Yang L, Bing X, Song L, Na C, Minghong D, Annuo L. Intracavitary electrocardiogram guidance for placement of peripherally inserted central catheters in premature infants. *Medicine* [Internet]. 2019 [cited 2021 May 20]; 98(50):e18368. DOI: <http://dx.doi.org/10.1097/MD.00000000000018368>.
27. Zhou LJ, Xu HZ, Xu MF, Hu Y, Lou XF. An Accuracy Study of the Intracavitary Electrocardiogram (IC-ECG) Guided Peripherally Inserted Central Catheter Tip Placement among Neonates. *Open Med (Wars)* [Internet]. 2017 [cited 2021 May 20]; 12:125-30. DOI: <https://doi.org/10.1515/med-2017-0019>.
28. Ben Fadel N, Pulgar L, Khurshid F. Point of care ultrasound (POCUS) in Canadian neonatal intensive care units (NICUs): where are we? *J Ultrasound* [Internet]. 2019 [cited 2021 May 20]; 22(2):201-6. DOI: <https://doi.org/10.1007/s40477-019-00383-4>.
29. Ling Q, Chen H, Tang M, Qu Y, Tang B. Accuracy and Safety Study of Intracavitary Electrocardiographic Guidance for Peripherally Inserted Central Catheter Placement in Neonates. *J Perinat Neonatal Nurs* [Internet]. 2019 [cited 2021 May 20]; 33(1):89-95. DOI: <https://doi.org/10.1097/JPN.0000000000000389>.
30. Zhou L, Xu H, Liang J, Xu M, Yu J. Effectiveness of Intracavitary Electrocardiogram Guidance in Peripherally Inserted Central Catheter Tip Placement in Neonates. *J Perinat Neonatal Nurs* [Internet]. 2017 [cited 2021 May 20]; 31(4):326-31. DOI: <https://doi.org/10.1097/JPN.0000000000000264>.
31. Agência Nacional de Vigilância Sanitária (Br). Medidas de prevenção de infecção relacionada à assistência à saúde. Brasília (DF): Anvisa, 2017.
32. Pettit J. Trimming of Peripherally Inserted Central Catheters: The End Result. *JAVA* [Internet]. 2006 [cited 2021 May 20]; 11(4):208. DOI: <https://doi.org/10.2309/java.11-4-12>.
33. Steele D, Norris CM. Cutting peripherally inserted central catheters may lead to increased rates of catheter-related deep vein thrombosis. *J Infus Nurs* [Internet]. 2014 [cited 2021 May 20]; 37(6):466-72. DOI: <https://doi.org/10.1097/NAN.0000000000000073>.
34. Jahagirdar D, Featherstone R. Trimmed peripherally inserted central catheters for hospitalized Neonatal Patients: A Review of Safety and Guidelines. Ottawa (ON): Canadian Agency for Drugs and Technologies in Health [Internet]; 2019 [cited 2021 Apr 12]. Available from: <https://www.ncbi.nlm.nih.gov/books/NBK550559/>.
35. Valadão VPC, Reis AT, Araújo BBM, Sá Neto JA, Pacheco STA, Marta CB. Evaluation of thermal blanket use in newborns submitted to the peripherally inserted central venous catheter installation. *Nursing* [Internet]. 2019 [cited 2021 Jun 10]; 22(259):3419-25. Available from: <http://www.revistanursing.com.br/revistas/259/pg61.pdf>.

36. Conway MA, McCollom C, Bannon C. Central Venous Catheter Flushing Recommendations: A Systematic Evidence-Based Practice Review. *J Pediatr Oncol Nurs* [Internet]. 2014 [cited 2021 May 20]; 31(4):185-90. DOI: <https://doi.org/10.1177/1043454214532028>.
37. Ullman AJ, Bulmer AC, Dargaville TR, Rickard CM, Chopra V. Antithrombogenic peripherally inserted central catheters: overview of efficacy and safety. *Expert Rev Med Devices* [Internet]. 2019 [cited 2021 Jun 05]; 16(1):25-33. DOI: <https://doi.org/10.1080/17434440.2019.1555466>.
38. Liang H, Zhang L, Guo X, Sun L. Vancomycin-lock therapy for prevention of catheter-related bloodstream infection in very low body weight infants. *BMC Pediatr* [Internet]. 2021 [cited 2021 Jun 07]; 21(1):3. DOI: <https://doi.org/10.1186/s12887-020-02482-2>.
39. Sathiyamurthy S, Banerjee J, Godambe SV. Antiseptic use in the neonatal intensive care unit - a dilemma in clinical practice: An evidence-based review. *World J Clin Pediatr* [Internet]. 2016 [cited 2021 Jun 05]; 5(2):159-71. DOI: <https://doi.org/10.5409/wjcp.v5.i2.159>.
40. Rickard CM, Marsh NM, Webster J, Gavin NC, Chan RJ, McCarthy AL, et al. Peripherally inserted central catheter dressing and securement in patients with cancer: the PISCES trial. Protocol for a 2x2 factorial, superiority randomised controlled trial. *BMJ Open* [Internet]. 2017 [cited 2021 Jun 05]; 7(6):e015291. DOI: <https://doi.org/10.1136/bmjopen-2016-015291>.